Check for updates

Stroke

TOPICAL REVIEW

Acute Management of Medium Vessel Occlusion Stroke: New Evidence and a Path Forward

William K. Diprose, MD*; Umberto Pensato, MD*; Mohammed Almekhlafi, MD; Marios-Nikos Psychogios, MD; Urs Fischer, MD; Frédéric Clarençon, MD, PhD; René Chapot, MD; Wei Hu, MD, PhD; Thanh N. Nguyen, MD; Shinichi Yoshimura, MD, PhD; Kazutaka Uchida, MD, PhD; Bernard Yan, MD; Bijoy K. Menon, MD; Mayank Goyal, MD, PhD; Michael D. Hill, MD; Johanna M. Ospel, MD, PhD

ABSTRACT: Acute stroke due to medium vessel occlusion (MeVO) accounts for 25% to 40% of all acute ischemic stroke cases and is associated with substantial morbidity despite current best medical management. This motivated several recently published and ongoing trials that investigate(d) the benefit of endovascular thrombectomy (EVT) for MeVO stroke. Two of these trials have been published, an interim analysis of a third has been presented, and a fourth will be presented soon. The available trial results suggest no difference in outcomes between EVT and best medical management, and a possibility of harm with EVT. Preliminary post hoc analyses have however identified promising patient subgroups that may derive benefit from EVT. Improving EVT tools and techniques, together with adjunctive treatments, may further increase the technical efficacy of MeVO EVT. This review summarizes clinical and imaging features of MeVO stroke, reviews current evidence for medical and endovascular treatment, discusses recent MeVO EVT trial results, and outlines possible pathways forward for future MeVO trials.

GRAPHIC ABSTRACT: A graphic abstract is available for this article.

Key Words: ischemia ■ ischemic stroke ■ middle cerebral artery ■ morbidity ■ prognosis

Downloaded from http://ahajournals.org by on March 16, 2026

Acute ischemic stroke (AIS) is a leading cause of mortality and long-term disability worldwide.[1] It results from an acute disruption of cerebral blood flow due to a vessel occlusion or stenosis, leading to a time-dependent cascade of ischemic injury.[2] Depending on the size of the occluded artery, AIS can be classified as either large vessel occlusion (LVO) stroke (ie, occlusions of the large and proximal intracranial arteries) or medium vessel occlusion (MeVO)/distal and medium vessel occlusion sroke (DMVO; ie, occlusions of smaller, more distal arteries, with the terms MeVO and DMVO often being used interchangeably). MeVO accounts for 25% to 40% of all AIS cases,[3,4] and although their prognosis is more favorable compared with LVO, AIS due to MeVO remains associated with substantial morbidity despite current best medical management.[4–6]

The extent, severity, and duration of ischemia caused by the occluded artery determine how much of the salvageable ischemic tissue (penumbra) transforms into irreversible infarction[7] and how quickly this transformation occurs. Rapid recanalization of the target occlusion and reperfusion of the downstream tissue, which aims to interrupt this progression, represents the cornerstone of AIS management.[5,6] Intravenous thrombolysis (IVT) has demonstrated its efficacy across a spectrum of vessel occlusions causing disabling symptoms,[8–12] whereas endovascular thrombectomy (EVT) has only demonstrated benefit in LVO stroke to date.[13]

Given the remarkable benefits observed with EVT in patients with anterior and posterior LVO stroke,[13,14] including those with unfavorable prognostic factors at baseline such as extended time window presentation[15,16] or large

Correspondence to: Johanna M. Ospel, MD, PhD, Department of Radiology, Foothills Medical Centre, University of Calgary, 1403 29th St NW, Calgary, AB T2N2T9, Canada. Email johanna.ospel@ucalgary.ca
*W.K. Diprose and U. Pensato contributed equally.
Supplemental Material is available at https://www.ahajournals.org/doi/suppl/10.1161/STROKEAHA.125.050401.
For Sources of Funding and Disclosures, see page 825.
© 2025 American Heart Association, Inc.
Stroke is available at www.ahajournals.org/journal/str

baseline ischemic core,[17] interest has grown in extending EVT to more distal vessel occlusions.[3] However, 3 recent trials have dampened this enthusiasm, as they showed no benefit of EVT in patients with MeVO stroke.[5,6,18–20]

In this review, we examine the definitions, clinical presentation, and current evidence for guiding acute treatment of MeVO stroke. We also critically review key findings from published and presented MeVO EVT trials and discuss their implications for future research and clinical practice.

WHAT IS A MEDIUM-SIZED VESSEL OCCLUSION?

There is no universal, standardized definition of a medium-sized intracranial vessel, and some authors prefer the term DMVO over medium-sized vessel occlusion (MeVO).[3] However, the 2 definitions largely overlap.

The definition of MeVO or DMVO is typically anchored in (1) the anatomic vessel segment affected by the occlusion, which is commonly defined by the number of branch points before the occlusion; (2) the vascular territory supplied by this vessel; (3) the vessel diameter (which is directly related to the size of the supplied territory); and (4) the clinical deficit (Table S1).[3,21] Based on these features, a, somewhat arbitrary, distinction is made between MeVO and LVO. As a result, there have been different definitions of MeVO across the clinical trials. For example, the DISTAL (Endovascular Therapy Plus Best Medical Treatment Versus Best Medical Treatment Alone for Medium Distal Vessel Occlusion Stroke),[6] DISCOUNT (Evaluation of Mechanical Thrombectomy in Acute Ischemic Stroke Related to a Distal Arterial Occlusion),[18] FRONTIER-AP (Randomized Controlled Trial of the Clinical Outcome and Safety of Endovascular Versus Standard Medical Therapy for Stroke With Medium Sized Vessel Occlusion), and ORIENTAL-MeVO (Endovascular Treatment in Acute Intracranial Distal Medium Vessel Occlusion Stroke)[22] trials included A1 segment occlusion in their MeVO definition, while the ESCAPE-MeVO trial (Endovascular Treatment to Improve Outcomes for Medium Vessel Occlusions) did not.[5]

In practical terms, an intracranial artery distal to the terminal internal carotid artery and M1 segment of the middle cerebral artery (MCA) with a diameter ranging between 0.75 and 2 mm would fall into the MeVO category.[3] Generally, this encompasses the nondominant or distal M2 or M3 segments of the MCA, the A2 or A3 segments of the anterior cerebral artery (ACA), and the P2 or P3 segments of the posterior cerebral artery (PCA). Some authors also include the A1, P1, and M4 segments, the posterior inferior cerebellar, anterior inferior cerebellar artery, and superior cerebellar arteries in the definition of MeVO/DMVO,[23] and some authors exclude proximal M2 occlusions from this definition.[24]

ANATOMY AND CLINICAL PRESENTATION

Great variability in anatomic location and clinical presentation is a hallmark feature of MeVO stroke, rendering both the clinical and radiological diagnosis challenging. A detailed description of anatomic and clinical features of MeVO stroke, depending on the exact MeVO location, is provided in Appendix S1.[4–6,25–35]

Most MeVOs (70%–85%) are found in the MCA territory.[4–6] Diagnosis and endovascular treatment can be complicated by variable MCA branching patterns, such as MCA trifurcations and large, M2-like anterior temporal arteries.[25,27] Clinical manifestations of MCA MeVO stroke are also highly variable, ranging from being clinically silent, to fleeting symptoms, to severely disabling or even fatal stroke.

The PCA is the second most common site of MeVO, accounting for ≈10% to 20% of MeVO strokes.[4–6] A common anatomic variation is the fetal-type PCA, in which the P1 segment is absent or the posterior communicating artery is larger than the P1 segment, in which case endovascular access to the occlusion is via the internal carotid artery.[31]

The most common clinical syndrome associated with PCA MeVO stroke is contralateral homonymous hemianopia or (usually superior) quadrantanopia although disorders of higher order visual processing, such as visual agnosias, alexia, and achromatopsia, may also occur.[32]

The ACA is the third most common site of MeVO, accounting for ≈5% of MeVO strokes.[4–6] EVT for ACA MeVOs can be complicated by anatomic variations such as hypoplastic or absent A1 segments that require endovascular access via the contralateral A1 segment and anterior communicating artery.

The most common symptom in isolated ACA occlusion is contralateral leg weakness and sensory loss,[34] and more anterior infarcts may present with a frontal lobe behavioral syndrome such as abulia.[35]

CLINICAL COURSE OF MEVO PATIENTS NOT TREATED WITH THROMBECTOMY

As the diameter of the occluded vessel decreases, the volume of the ischemic brain tissue usually diminishes, leading to a milder clinical presentation and a more favorable prognosis. Consequently, the clinical course of MeVO stroke is generally better than that of LVO stroke.

In the HERMES (Highly Effective Reperfusion Evaluated in Multiple Endovascular Stroke Trials) patient-level meta-analysis of LVO EVT trials, the median baseline National Institutes of Health Stroke Scale (NIHSS) score was 17 compared with 8 in ESCAPE-MeVO and 6 in DISTAL.[5,6,13] In the HERMES subgroup analysis of M2 occlusions, the median NIHSS score was 14.[36] Similarly, in the multicenter STOP Stroke study (Significance of Large

Downloaded from http://ahajournals.org by on March 16, 2026

Vessel Intracranial Occlusion Causing Acute Ischemic Stroke and TIA Study), mean baseline NIHSS scores were 11.5 for M2 occlusions, 12.4 for A2 occlusions, and 10.4 for P2 occlusions.[37] The TOPMOST (Thrombectomy for Primary Distal Posterior Cerebral Artery Occlusion Stroke) study group reported a median baseline NIHSS score of 6 in patients with P2-P3 occlusions and 9 for A2-A3 occlusions,[38] whereas the PLATO study (Posterior Cerebral Artery Occlusion Study) of P1-P3 occlusions reported a baseline NIHSS score of 8 in the EVT group versus 5 in the medically managed group.[39]

Unsurprisingly, outcomes with medical management are better in MeVO stroke compared with LVO stroke. The HERMES meta-analysis showed that 12.9% of patients with medically managed LVO achieved a modified Rankin Scale (mRS) score of 0 to 1, 26.5% achieved an mRS score of 0 to 2, and 18.9% died at 90 days.[13] In comparison, in the control arms of the ESCAPE-MeVO and DISTAL trials, 37.6% and 43.1% achieved an mRS score of 0 to 1, and 54.7% and 58.8% achieved an mRS score of 0 to 2 at 90 days, respectively.[5,6] Mortality rates were also lower than in LVO, 8.4% in ESCAPE-MeVO and 15.2% in DISTAL.[5,6] In the multicenter STOP Stroke study, only 40% of patients with M2 occlusions achieved an mRS score of 0 to 2, and mortality was 24%.[37] Even fewer patients with ACA and PCA occlusions achieved an mRS score of 0 to 2 (only 23%) although mortality was lower at 8%.

The PLATO study reported that among medically managed patients, 27% and 53% of those with P1-P3 occlusions achieved an mRS score of 0 to 1 and 0 to 2, respectively, at 90 days.[39] For A2-A3 occlusions in TOPMOST, these numbers were 35.7% and 50%, respectively.[40]

ACUTE REPERFUSION THERAPY FOR MEVO: IVT

Evidence supporting the use of IVT in MeVO stroke is derived from landmark trials of IVT conducted before the routine use of vascular imaging.[8,9] Patients with MeVO stroke presenting within 4.5 hours of stroke onset and without contraindications to IVT stand to benefit from the administration of IV alteplase (0.9 mg/kg) or IV tenecteplase (0.25 mg/kg).[9,41] Subsequent efforts have sought to better characterize the impact of IVT in patients with MeVO using posttreatment computed tomography (CT) angiography. In a pooled analysis of the INTERRSeCT (Association of Clinical, Imaging, and Thrombus Characteristics With Recanalization of Visible Intracranial Occlusion in Patients With Acute Ischemic Stroke Study) and PRoveIT (Precise and Rapid Assessment of Collaterals Multi-Phase CTA in the Triage of Patients With Acute Ischemic Stroke for IA Therapy Study) studies, 258 patients with MeVO were identified, including 74 (28.7%) proximal M2 occlusions, 88 (34.1%) distal M2, 57 (22.1%) M3, 12 (4.7%) A2-A3, and 27 (10.5%) P2-P3 occlusions. Among them, 186 (72.1%) patients were treated with IV alteplase.[4] Recanalization was observed in 21.4% (9/42) patients who were not treated with IV alteplase compared with 47.2% (75/159) patients treated with IV alteplase. Early recanalization was associated with excellent functional outcome (adjusted odds ratio, 2.29 [95% CI, 1.23–4.28]), and although the direction of effect favored IV alteplase, the association with excellent functional outcome did not reach statistical significance (adjusted odds ratio, 1.70 [95% CI, 0.88–3.25]).[4]

IVT in the Late Therapeutic Window (≥4.5 Hours)

The EXTEND trial (Thrombolysis Guided by Perfusion Imaging up to 9 Hours After Onset of Stroke Trial) randomized patients presenting between 4.5 and 9.0 hours after the onset of stroke, or those who awoke with stroke symptoms (if within 9 hours from the midpoint of sleep), to receive either IV alteplase or placebo.[42] Eligibility criteria required evidence of salvageable brain tissue on CT perfusion imaging. Overall, the IV alteplase group was more likely to have no or minor neurological deficits at follow-up compared with the placebo group. A total of 225 patients were randomized, including 159 (70.7%) with LVO, 56 (24.9%) with M2 occlusions (including both LVO and non-LVO definitions), 41 (18.2%) with M3-M4 occlusions, 10 (4.4%) with PCA occlusions, and 3 (1.3%) with ACA occlusions. A prespecified subgroup analysis demonstrated a similar effect size between large vessel (adjusted risk ratio, 1.45 [95% CI, 0.89–2.35]) and non-large vessel (≈ medium vessel) occlusions (adjusted risk ratio, 1.46 [95% CI, 0.85–2.50]).[42] Similarly, the WAKE-UP trial (Efficacy and Safety of MRI-Based Thrombolysis in Wake-Up Stroke) randomized patients with an acute ischemic lesion visible on diffusion-weighted magnetic resonance imaging without corresponding hyperintensity on fluid-attenuated inversion recovery images (DWI-FLAIR mismatch) to IV alteplase or placebo.[43] Compared with the placebo group, the IV alteplase group had significantly higher odds of a favorable outcome at 90 (adjusted odds ratio, 1.61 [95% CI, 1.09–2.36]) days. A post hoc analysis of WAKE-UP identified 187/503 (37.2%) with any visible vessel occlusion, including 58 (31.0%) with an MCA branch occlusion (ie, beyond the M1 segment), 18 (9.6%) with a PCA occlusion, and 2 (1.1%) with an ACA occlusion. Among patients with a non-LVO (ie, a medium or distal vessel) occlusion, the treatment effect estimate remained consistent with the overall trial result (adjusted odds ratio, 1.65 [95% CI, 1.08–2.51]).[44] Finally, the HOPE trial (Alteplase for Acute Ischemic Stroke at 4.5 to 24 Hours) randomized patients presenting within 4.5 and 24 hours after stroke onset with salvageable brain tissue on CT perfusion imaging

Downloaded from http://ahajournals.org by on March 16, 2026

to either IV alteplase or no IV alteplase. Patients were not enrolled if EVT was planned. In 80 of 372 patients with M2 occlusions, IV alteplase was associated with a higher likelihood of excellent functional outcome at 90 (adjusted risk ratio, 2.03 [95% CI, 1.05–3.92]) days.[11]

IVT for Non-Disabling Stroke

The TEMPO-2 trial (Tenecteplase Versus Standard of Care for Minor Ischemic Stroke With Proven Occlusion) randomized patients with minor AIS and either intracranial occlusion or focal perfusion abnormality to receive IV tenecteplase (0.25 mg/kg) or non-thrombolytic standard of care.[45] The median baseline NIHSS score was 2 (interquartile range, 1–3), reflecting the mild clinical syndromes of the included patients. Of the 884 patients randomized, 480 (54.3%) had an MeVO, defined as occlusion of the M2 segment of the MCA or more distal, or the A2 segment of the anterior cerebral artery or more distal. IV tenecteplase was not superior to control (risk ratio, 0.94 [95% CI, 0.84–1.05]), suggesting that patients with MeVO with non-disabling neurological deficits should not receive IV thrombolysis.

Intravenous Tenecteplase Versus Intravenous Alteplase

A post hoc analysis of the AcT trial (Intravenous Tenecteplase Compared With Alteplase for Acute Ischemic Stroke in Canada),[41,46] which randomized 1577 patients with AIS eligible for IVT to either IV alteplase (0.9 mg/kg) or IV tenecteplase (0.25 mg/kg), identified 455 (28.9%) patients with MeVO. Occlusion locations included proximal nondominant M2 (27.5%), distal M2 (16.3%), M3/M4 (35.2%), A2/A3/A4 (7.5%), and P2/P3/P4 (13.6%). Of these, 87 of 455 (19.1%) underwent EVT in addition to receiving IVT. Among patients with MeVO, excellent clinical outcomes (mRS score, 0–1) at 90 days were similar between the 2 treatment groups: 37.9% in the IV tenecteplase group versus 34.7% in the IV alteplase group. However, in the subset of patients who underwent EVT, initial successful reperfusion (expanded Thrombolysis in Cerebral Infarction [eTICI] score, 2b-3) was nominally higher in the IV tenecteplase group compared with the IV alteplase group (13.0% versus 7.5%). Final successful reperfusion rates were also higher with tenecteplase compared with alteplase (71.7% versus 60.0%; adjusted risk ratio, 1.29 [95% CI, 1.04–1.61]). Although direct evidence of tenecteplase superiority over alteplase in patients with MeVO is lacking, the consistent trend toward higher recanalization rates, improved functional outcome, and the practical advantage of single-bolus administration over a 1-hour infusion support the use of tenecteplase in patients with MeVO.[47,48]

Collectively, current data support the use of IVT, preferably tenecteplase, as the standard of care for patients with MeVO presenting with disabling symptoms within the early time window and no absolute contraindication or in the extended window when imaging demonstrates the presence of salvageable brain tissue. This approach is consistent with current stroke guidelines.[9,49,50]

ACUTE REPERFUSION THERAPY FOR MEVO: EVT

The technical evolution of devices, techniques, and expertise since the positive landmark EVT trials for LVO stroke has made EVT for MeVO stroke a realistic treatment possibility, and the substantial disability associated with MeVO stroke despite standard-of-care treatment including IVT[51,52] has led to a growing interest in EVT for MeVO stroke. Initial support came from several small, non-randomized studies suggesting that EVT is both safe and potentially effective for MeVO stroke.[53] A post hoc analysis of the HERMES collaboration showed a benefit of EVT in patients with proximal, large M2 occlusions included in those trials.[36] Observational registries have further reinforced this evidence by generally showing a favorable safety profile of EVT for MeVO stroke.[29,38–40,51,52] Given this growing body of promising observational data, at least 5 phase 3 randomized controlled trials with clinical end points were (or are being) conducted to assess whether EVT provides additional benefit over best medical management in MeVO stroke: ESCAPE-MeVO, DISTAL, DISCOUNT, FRONTIER-AP, ORIENTAL-MeVO.[5,6,18,22] Another MeVO EVT trial (the Japanese RESCUE-M2O trial [Randomized Clinical Trial of Endovascular Therapy for Acute Ischemic Stroke With Occlusion of the M2 Segment of Middle Cerebral Artery]) will start soon. In addition, the DISTALS trial (Endovascular Treatment for Stroke due to Occlusion of Medium or Distal Vessels; NCT05152524), which tests the efficacy of the Tigertriever system (Rapid Medical) for AIS due to more distal occlusions, uses reperfusion success on imaging as the primary outcome. At the time of writing (November 2025), the results of ESCAPE-MeVO and DISTAL have been published, and the DISCOUNT interim results were presented at the International Stroke Conference in February 2025. The baseline characteristics of the participants included in these trials are summarized in Table S2, and their results are discussed in the following.

Trial Design

ESCAPE-MeVO and DISTAL were multicenter, prospective, phase 3, randomized, controlled trials, with open-label treatment assignment and blinded outcome evaluation.[5,6] They compared EVT plus usual care to usual care alone in patients with AIS caused by a medium vessel (or distal) occlusion. Overall, their inclusion criteria were similar.[54,55] ESCAPE-MeVO included patients with

Downloaded from http://ahajournals.org by on March 16, 2026

stroke onset within 12 hours, an NIHSS score ≥3 with a disabling deficit (eg, aphasia), and with an occlusion of the M2, M3, A2-A3, or P2-P3 segment. Patients without salvageable brain tissue on neuroimaging or with baseline disability requiring assistance with activities of daily living were excluded. DISTAL included patients up to 24 hours after stroke onset (if there was salvageable brain tissue on CT perfusion or magnetic resonance imaging) and with an NIHSS score ≥4 or a clearly disabling neurological deficit. Occlusion locations differed from ESCAPE-MeVO, including codominant/nondominant M2, M3-M4, A1-A3, and P1-P3 occlusions. The trial was more inclusive with respect to baseline disability, excluding only patients who were bedridden or institutionalized. ESCAPE-MeVO mandated that the first thrombectomy attempt used a Solitaire X family stent retriever, with or without an aspiration catheter, whereas DISTAL left the device choice for the first thrombectomy pass to the interventionalists' discretion.

Technical Neurointerventional Aspects

Both studies assessed the technical efficacy of EVT with a modified version of the eTICI score, where only the affected vascular territory downstream to the medium (or distal) vessel occlusion, rather than the entire vascular territory, was used as a comparator. ESCAPE-MeVO termed the grading system the MeVO eTICI score (range, 0–3, with higher scores indicating greater reperfusion).[53] The technical efficacy of EVT was comparable between the 2 trials, with final MeVO eTICI score of 2b-3, MeVO eTICI score of 2c-3, and MeVO eTICI score of 3 of 75.1% and 71.7%, 52.6% and 55.8%, and 34.4% and 31.9% in ESCAPE-MeVO and DISTAL, respectively. In ESCAPE-MeVO, 15% of patients randomized to EVT did not require thrombectomy, as they had already experienced recanalization by the time of the baseline digital subtraction angiogram. In DISTAL, 2.6% of patients randomized to EVT did not undergo digital subtraction angiogram due to symptom resolution, and an additional 8.5% had spontaneous clot lysis or fragmentation on the baseline digital subtraction angiogram that obviated the need for EVT.

Safety Outcomes

Safety outcomes were neutral, with a possibility of harm in the EVT arms. The 90-day mortality rate was nominally higher in the EVT arm than in the usual care arm of ESCAPE-MeVO (13.3% versus 8.4%) and slightly higher in the DISTAL trial (15.5% versus 14.0%). There are several possible explanations for this. Serious adverse events were more common in the EVT group than in the usual care group, both in ESCAPE-MeVO (33.9% versus 25.7%) and DISTAL (42.0% versus 32.4%). Although immediate procedural complications such as vessel injury were rare in the EVT arms (1.2% [ESCAPE-MeVO]/3% [DISTAL]), some delayed events, such as symptomatic intracranial hemorrhage (5.4% versus 2.2% [ESCAPE-MeVO]/5.9% versus 2.6% [DISTAL]) or stroke progression (5.4% versus 1.8% in ESCAPE-MeVO), may have been caused by the EVT procedure. Pneumonia (7.0% versus 3.3% [ESCAPE-MeVO]/7.1% versus 5.7% [DISTAL]) and other infections (1.8% versus 1.2% urinary tract infections and 2.7% versus 1.5% other infections [ESCAPE-MeVO]/8.0% versus 4.5% infections in DISTAL) were all more frequently observed in the EVT groups, which could be plausibly related to procedural sedation or general anesthesia.

Efficacy Results

Both trials used the mRS score at 90 days to assess efficacy outcomes. The primary outcome in ESCAPE-MeVO was an excellent functional outcome (mRS score, 0–1), whereas DISTAL used the ordinal mRS. ESCAPE-MeVO failed to show a benefit of EVT, with 41.6% of EVT patients and 43.1% of usual care patients achieving an excellent functional outcome at 90 days (adjusted rate ratio, 0.95 [95% CI, 0.79–1.15]).[5] Similarly, DISTAL reported no significant difference in the distribution of mRS scores observed at 90 days (common odds ratio for improvement in 90-day mRS score, 0.90 [95% CI, 0.67–1.22]).[6] Follow-up infarct volumes were similar in ESCAPE-MeVO, with a mean volume of ≈30 mL in both groups. Infarct volumes were not reported in DISTAL. Preliminary results from the DISCOUNT trial, a prospective, multicenter, open-label, randomized controlled trial that sought to enrol a total of 488 patients with distal/MeVO stroke across 22 French centers, added further uncertainty.[18] In a planned interim analysis of the first 163 patients, 60% of those treated with EVT and 77% of those receiving usual care achieved an mRS score of 0 to 2 at 90 days. After imputation of missing data, EVT was associated with significantly lower odds of a good outcome (odds ratio, 0.42; P=0.02). The trial was stopped after review of the results of this interim analysis.

Subgroup Analyses

Effect size estimates for subgroups in ESCAPE-MeVO indicate that early treatment with EVT (<260 minutes from onset to randomization) may provide some benefit (risk ratio for mRS score, 0–1, 1.21 [95% CI, 0.94–1.55]), whereas treatment with EVT beyond this time window may cause harm (risk ratio for mRS score, 0–1, 0.75 [95% CI, 0.57–0.99]). However, the effect size estimate for early presenters (<360 minutes) in DISTAL favored usual care over EVT (common odds ratio for improvement in mRS score, 0.82 [95% CI, 0.56–1.20]). Furthermore, there was a signal towards EVT benefit in patients with good collateral status on baseline CT angiography

Downloaded from http://ahajournals.org by on March 16, 2026

Table. Common Explanations for the Neutral MeVO EVT Trials, the Evidence Behind Them, and Possible Mitigation Strategies

Reason	Explanation	Evidence	Plausibility	Mitigation strategies
Reperfusion rates were not high enough.	Final eTICI scores* were lower compared with LVO EVT trials.	Successful reperfusion (final eTICI score, 2b-3) was achieved in 66% (DISTAL)/75% (ESCAPE-MeVO),[5] lower than in recent LVO EVT trials (89%).[57] Final eTICI score was a strong predictor of outcomes in the ESCAPE-MeVO EVT arm.[58]	Possible	Development of new improved EVT tools and devices Intra-arterial thrombolytics to augment reperfusion
There were too many procedural complications.	Navigating in the distal arterial tree and in smaller, more fragile vessels is more prone to causing complications (perforations and dissections).	sICH did not differ significantly between the EVT (5%–6%) and control arms (2%–3%). Intracranial vessel perforation during EVT occurred in 3% in DISTAL/<1% in ESCAPE-MeVO.	Unclear	Although the neutral trial outcomes cannot be explained by technical complications, developing newer, improved MeVO EVT tools and techniques is, nevertheless, desirable.
In-hospital EVT workflows were too slow.	Discussions about (1) equipoise, (2) consenting patient and family, and (3) technical feasibility, as well as the need to organize general anesthesia for patient compliance, may have increased treatment delays and, therefore, diminished EVT benefit.	Median time from imaging to arterial puncture was 70 min in DISTAL/86 min in ESCAPE-MeVO vs 76 min in HERMES.[59]	Unclear	Choosing sites with good anesthesia availability Performing EVT under local anesthesia in compliant patients (though patient movement during distal navigation can pose safety challenges) Enabling remote consent
Selection bias	Patients with a favorable prognosis who were most likely to benefit from EVT were treated off-label outside the trials due to a lack of equipoise or other reasons.	Median NIHSS score was 6 (DISTAL)/8 (ESCAPE-MeVO) vs 7 in prospective cohort studies[4] and 8–10 in retrospective studies.[53] Median age was 77 (DISTAL)/75 (ESCAPE-MeVO) vs 72 in large prospective cohort studies.[53] Proximal M2 occlusions were less common in ESCAPE-MeVO (25%) than in prospective cohort studies (29%).[53]	Probable	Obtaining explicit commitment from sites to enroll all eligible patients Screening logs Concurrent registries to capture off-label treatments
Inclusion of patients with mild deficits (ie, NIHSS score 3–5)	The natural history of patients with mild deficits and MeVO is likely favorable.	DISTAL subgroup analysis suggests EVT benefit for patients with baseline NIHSS score >6.[6] The MAD MT, DUSK, and PLATO studies suggested the benefit of EVT with a higher baseline NIHSS score, with a threshold of ≥6 indicating benefit.[29,39,51,52]	Probable	Exclusion of patients with lower baseline NIHSS score in future clinical trials (ie, NIHSS score <6)
The time window for enrollment was too broad.	Late presentation due to mild deficits and the broad trial time windows (up to 12–24 h) may have increased treatment delays and diminished EVT benefit.	Median time from onset to randomization was 3.9 h in DISTAL/4.3 h in ESCAPE-MeVO vs 3.3 h in HERMES.[13] An ESCAPE-MeVO subanalysis suggests that patients treated within 3 h benefited from EVT.[5]	Possible	Narrower time window
There was no tissue left to salvage.	Imaging-based enrollment criteria in all trials were broad and inclusive. This may have led to the enrollment of patients with no salvageable tissue.	A DISTAL subanalysis suggests that patients with Tmax >6 s and volume >30 mL may benefit from EVT (Webinar presentation, June 16, 2025). An ESCAPE-MeVO subanalysis suggests that patients with moderate and good collaterals at baseline benefited from EVT.[56]	Possible	Stricter imaging enrollment criteria (exclude patients with large core on CTP and poor collaterals on CTA)
Too many patients who received IVT recanalized between qualifying baseline imaging and DSA	IVT may have recanalized occlusions before the first intracranial run so that there was no EVT target at the time of the DSA. This would be expected to occur equally in the EVT and control arms and may have diluted any treatment effect.	Distal clot migration occurred in 11% in DISTAL and 10% of ESCAPE-MeVO. In most of these patients, this resulted in distal migration to an EVT-amenable vessel segment rather than complete recanalization. In cohort studies of medically treated MeVOs, recanalization on 2–6 h follow-up CTA was achieved in 47% with vs 21% without IVT.	Unclear	In theory, restriction to IVT-ineligible patients could be a solution. However, this (1) excludes most early presenting patients (who are most likely to benefit), (2) causes equipoise concerns, (3) reduces generalizability, and (4) could prohibit use of adjunctive intra-arterial treatments (in cases of absolute contraindications for thrombolysis).
The mRS score is not granular enough to detect the treatment effect.	As a relatively gross functional outcome, the mRS score does not capture subtle EVT effects in MeVO stroke.	Although lower mRS categories were slightly more common, outcomes in both EVT and control arms in MeVO EVT trials were spread across the entire mRS spectrum, with mortality ranging between 13% and 15%. No benefit on any of the more granular secondary outcomes (EQ-5D-5L, Barthel index, and Lawton iADL) or follow-up infarct volume was seen.	Not plausible	Given the consistent neutral signal across all outcomes, it is unlikely that any alternative outcome would have shown EVT benefit. However, exploring additional outcome scores such as COSMOS[60] is generally recommended to explore outcome nuances in MeVO stroke in greater detail.

COSMOS indicates Canadian Outcome Scale for Minor Stroke; CTA, computed tomography angiography; CTP, computed tomography perfusion; DISTAL, Endovascular Therapy Plus Best Medical Treatment Versus BMT Alone for Medium Distal Vessel Occlusion STROKE; DSA, digital subtraction angiography; DUSK, Endovascular Versus Medical Management in Distal Medium Vessel Occlusion Stroke; EQ-5D-5L, EuroQol 5-dimensional, 5-level questionnaire; ESCAPE-MeVO, Endovascular Treatment to Improve Outcomes for Medium Vessel Occlusions; eTICI, expanded Thrombolysis in Cerebral Infarction; EVT, endovascular treatment; HERMES, Highly Effective Reperfusion Evaluated in Multiple Endovascular Stroke Trials; iADL, instrumental Activities of Daily Life; IVT, intravenous thrombolysis; LVO, large vessel occlusion; MAD MT, Multicenter Analysis of Primary Distal Medium Vessel Occlusions: Effect of Mechanical Thrombectomy; MeVO, medium vessel occlusion; mRS, modified Rankin Scale; NIHSS, National Institutes of Health Stroke Scale; PLATO, Posterior Cerebral Artery Occlusion Study; and sICH, symptomatic intracranial hemorrhage.

*Note that in this context, eTICI scores refer to MeVO eTICI, that is, the initially affected territory is considered the denominator for subsequent eTICI scoring, as described previously.[53]

Downloaded from http://ahajournals.org by on March 16, 2026

(mRS score, 0–1, 47% in the EVT arm versus 36% in the control arm), while EVT appeared to be harmful in those with poor collateral status (mRS score, 0–1, 25% in the EVT arm versus 37% in the control arm).[56] Unlike ESCAPE-MeVO, DISTAL showed a greater benefit of EVT with higher baseline stroke severity: common odds ratio was 0.76 (95% CI, 0.48–1.22) for NIHSS score ≤5, 1.02 (95% CI, 0.69–1.51) for NIHSS score >5, and 1.64 (95% CI, 0.83–3.23) for NIHSS score ≥10.

Effect size estimates were otherwise similar in both trials across different age groups, sex, geographic region, baseline Alberta Stroke Program Early Computed Tomography Score (<9 versus ≥9), IVT status (received versus not received), and occlusion site.

Interpretation of the Available Data

Overall, the available data from DISTAL, ESCAPE-MeVO, and DISCOUNT, particularly with the lack of any trend toward benefit and even a possibility of harm, were unexpected and interrupted a long series of positive EVT trials. With further examination, several possible explanations arise (Table).

First, MeVO strokes have a smaller brain tissue volume at risk than LVO strokes, which translates to milder baseline neurological deficits; there is less to gain with reperfusion. The median baseline NIHSS score in the HERMES meta-analysis of LVO trials was 17, whereas it was 8 in ESCAPE-MeVO and 6 in DISTAL. Notably, 41% of patients in DISTAL had an NIHSS score <5, suggesting that baseline deficits may have been too mild to show an improvement on the 90-day mRS. Moreover, the clinical eloquence of different brain regions is highly heterogeneous: small ischemic lesions sometimes cause disabling symptoms, whereas relatively large infarcts may result only in minor or negligible deficits.[61,62] The NIHSS might also be a suboptimal method for assessing symptom severity, particularly in posterior circulation MeVO

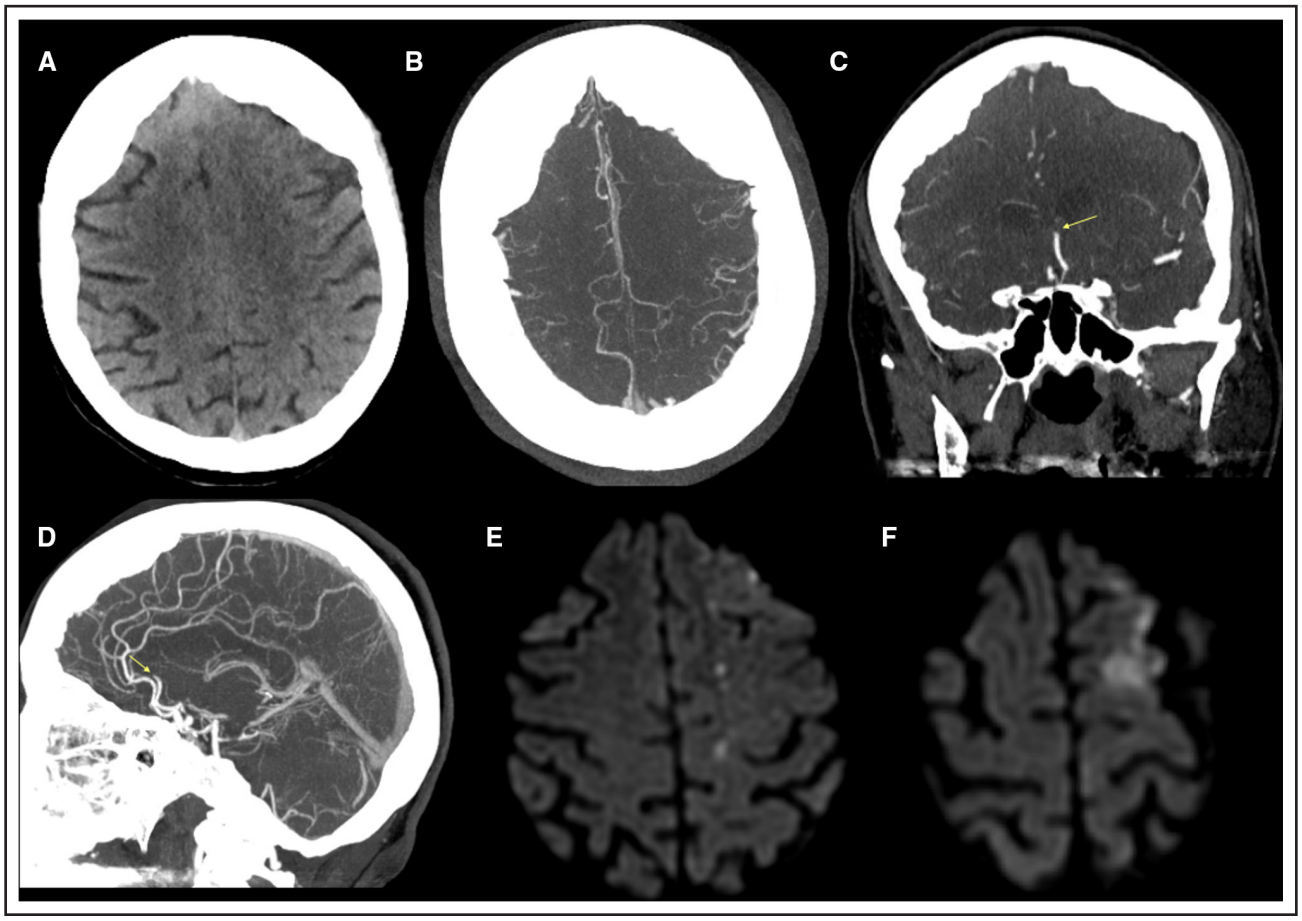

Figure 1. A female patient in her 70s was found by her family after falling on the floor confused, with right-sided weakness of unknown onset (National Institutes of Health Stroke Scale [NIHSS] score, 5).
Noncontrast computed tomography (CT) head (**A**) did not show any early ischemic changes. CT angiogram (**B**–**D**) showed a left-sided A2 occlusion. Although there is paucity of anterior cerebral artery branches in the left hemisphere in the axial reformations (**B**), the occlusion itself is better visible on coronal (**C**) and sagittal (**D**) reformations (arrows). The patient was randomized to intravenous tenecteplase in a clinical trial setting, and the team decided not to treat with endovascular treatment. She improved over the next 2 hours with a 24-hour NIHSS score of 1. Follow-up diffusion-weighted magnetic resonance imaging at 4 hours showed punctate small infarcts in the left anterior cerebral artery territory (**E** and **F**).

Downloaded from http://ahajournals.org by on March 16, 2026

strokes, where it might underestimate the true burden of disability.

Second, the likelihood of recanalization with IVT increases progressively as the occlusion becomes more distal, and as a result, the added benefit of EVT for achieving reperfusion is expected to be lower in MeVO compared with LVO (for exemplary cases, see Figures 1 and 2). The effect of EVT did not differ between patients receiving and not receiving IVT, and the rate of successful reperfusion on the initial angiographic run, obviating the need for EVT, so-called early reperfusion, was only 8.5% to 15%, which is similar to studies in LVO stroke.[63,64]

Third, the benefit of EVT is time-dependent, and while EVT has been shown to be effective in LVO within 6 hours from symptom onset, regardless of stroke progressor phenotype, the time dependency of EVT effect may be different in MeVOs and DMVOs. Given their more distal location in the arterial vascular tree, they functionally resemble end arteries and, by degrees, have less robust collateral support, potentially making patients with MeVO faster stroke progressors on average. As a result, the therapeutic time window for achieving meaningful reperfusion benefits in MeVO may be even shorter.

Fourth, imaging-based enrollment criteria have been extrapolated from LVO EVT trials, but whether they truly select patients who can benefit from EVT is unclear. Subgroup analyses from DISTAL and ESCAPE-MeVO suggest that patients with favorable perfusion and collateral profile (ie, imaging evidence of substantial tissue left to salvage) may benefit from EVT, while, in those with small penumbra or poor collateral profile, there was possible harm from EVT.[56]

Fifth, EVT for MeVOs presents a greater technical challenge than EVT for LVO, both in terms of safety and efficacy. While serious procedural complications (ie, vessel perforations) were rare in the 3 trials (Figure 3), other,

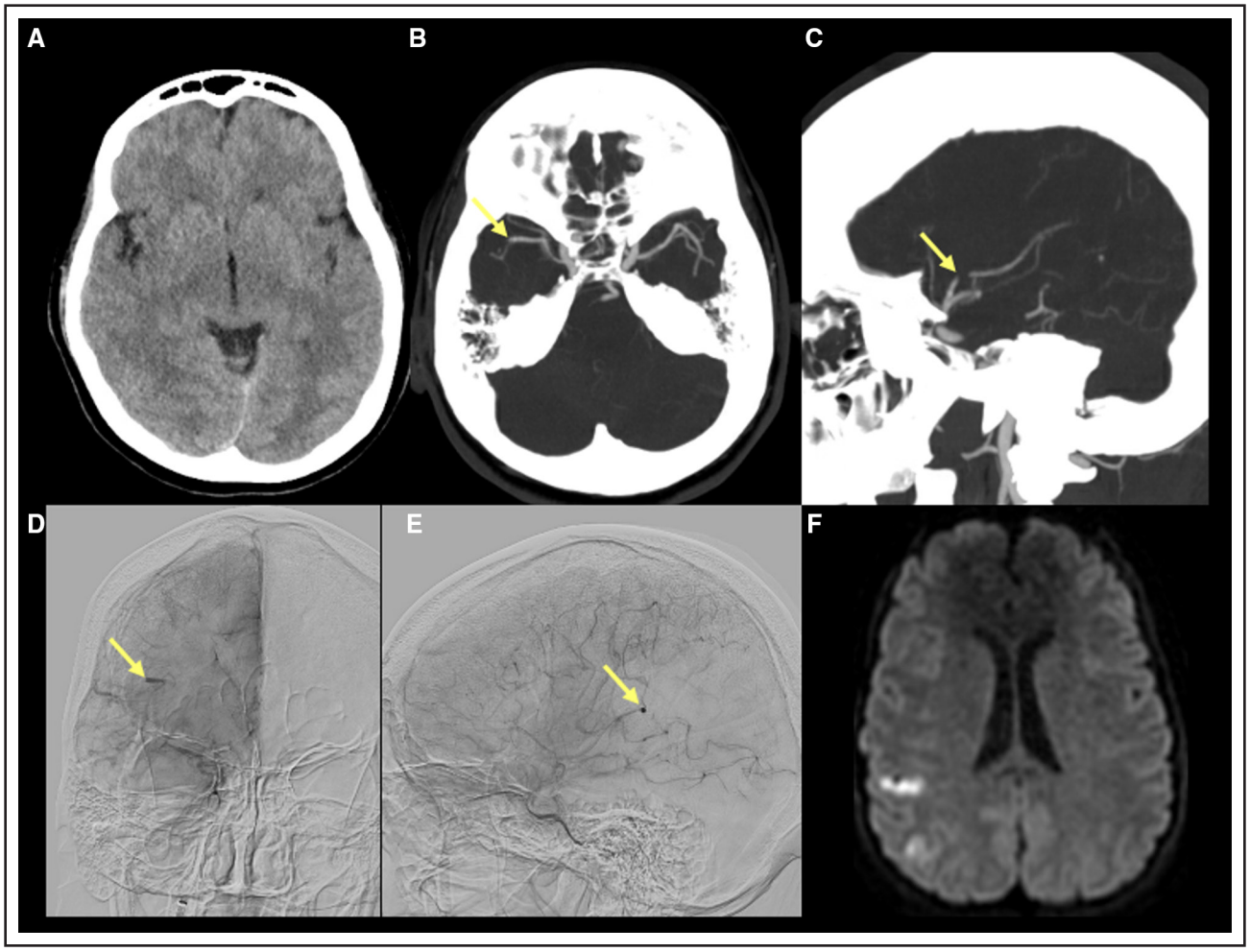

Figure 2. A female patient in her 30s admitted to the hospital for work-up of a cardiomyopathy was found by the nursing team to have sudden onset left-sided weakness and dysarthria (National Institutes of Health Stroke Scale score, 7).
Noncontrast computed tomography (CT) head (**A**) did not show early ischemic changes. CT angiogram (**B** and **C**) showed a right-sided proximal M2 occlusion (arrows). The patient was treated with intravenous tenecteplase and transferred for endovascular treatment. The patient was examined by the stroke team on the table and had markedly improved. At the first intracranial angiographic run (**D** and **E**), the proximal M2 occlusion had recanalized, and a posterior M3 occlusion was visible (arrows). The procedure was stopped. Diffusion-weighted magnetic resonance imaging at 24 hours (**F**) shows few small infarcts in the right parietal lobe.

Downloaded from http://ahajournals.org by on March 16, 2026

more subtle technical issues may have contributed to the results. Intracranial hemorrhage was more common in the EVT arms of the trials, most of which were subarachnoid hemorrhages that did not have an immediate clinical impact. Historically, these EVT-related small-volume subarachnoid hemorrhages were thought to be benign, but recent evidence suggests an association with poorer clinical outcomes.[65] ESCAPE-MeVO required stent retrievers as a first-line approach, and although DISTAL did not mandate an approach, stent retrievers were used in 80% of patients. It is not clear how a primarily aspiration-based approach would have altered the results, as there is insufficient evidence on how these 2 approaches compare in MeVO EVT specifically. Balloon-guide catheters, used in 38% of procedures in DISTAL, have been associated in some studies with increased mortality and worse functional outcomes,[66] whereas other studies have shown their use to be associated with improved revascularization and clinical outcomes in patients being treated with mainly stent retriever technique,[67,68] including in patients with MeVO.[69] Irrespective of the techniques used, both trials showed lower percentages of patients with successful reperfusion (75.1% in the ESCAPE-MeVO trial and 71.7% in DISTAL) than those achieved in previous EVT trials, where successful reperfusion rates are ≈90% (Figure 4).[57]

Other factors inherent to trial design and the enrolled patient population, rather than the treatment per se, might also have influenced the results. Patients in both trials were older than those in earlier EVT trials. The median

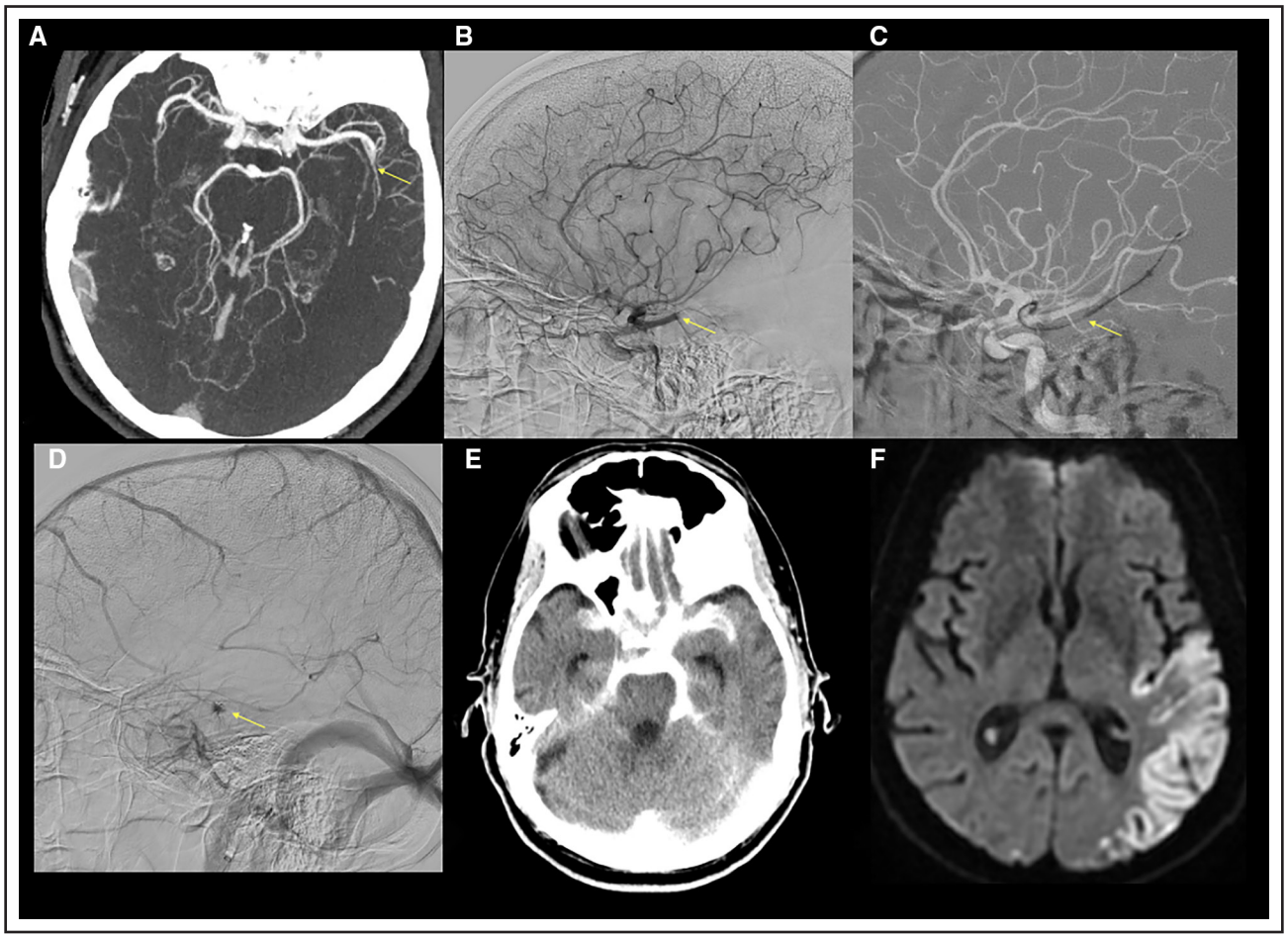

Figure 3. A male patient in their 60s presented with an acute onset of right-sided weakness.
Noncontrast computed tomography (CT) head (not shown) did not show any acute ischemic changes. CT angiogram head and neck showed a left proximal M2 occlusion (arrow in **A**). The patient's National Institutes of Health Stroke Scale (NIHSS) was initially 8 but worsened to 16 shortly after tenecteplase administration. Repeat noncontrast CT head and CT angiography (not shown) did not show any new findings. The patient was transferred to the neuroangiography suite for endovascular treatment. First angiographic run (lateral projection; **B**) shows the thrombus in unchanged location (arrow). **C**, An aspiration catheter was advanced over a microcatheter and microwire in the occluded segment. A total of 2 aspiration attempts were performed, and a subsequent angiographic run showed recanalization of the target occlusion and restored middle cerebral artery territory perfusion. However, there was a focus of contrast opacification (arrow in **D**) that persisted in the late venous phase, which was suspicious for extravasation. A noncontrast CT head was performed immediately after endovascular treatment (**E**) and confirmed a perforation with contrast in the subarachnoid spaces. The contrast cleared over the next hours and was not visible anymore on a repeat CT head the next day; 48-hour diffusion-weighted magnetic resonance imaging (**F**) showed a cortical infarct in the left posterior middle cerebral artery territory. Clinically, the patient improved and his NIHSS score at 48 hours was 3.

Downloaded from http://ahajournals.org by on March 16, 2026

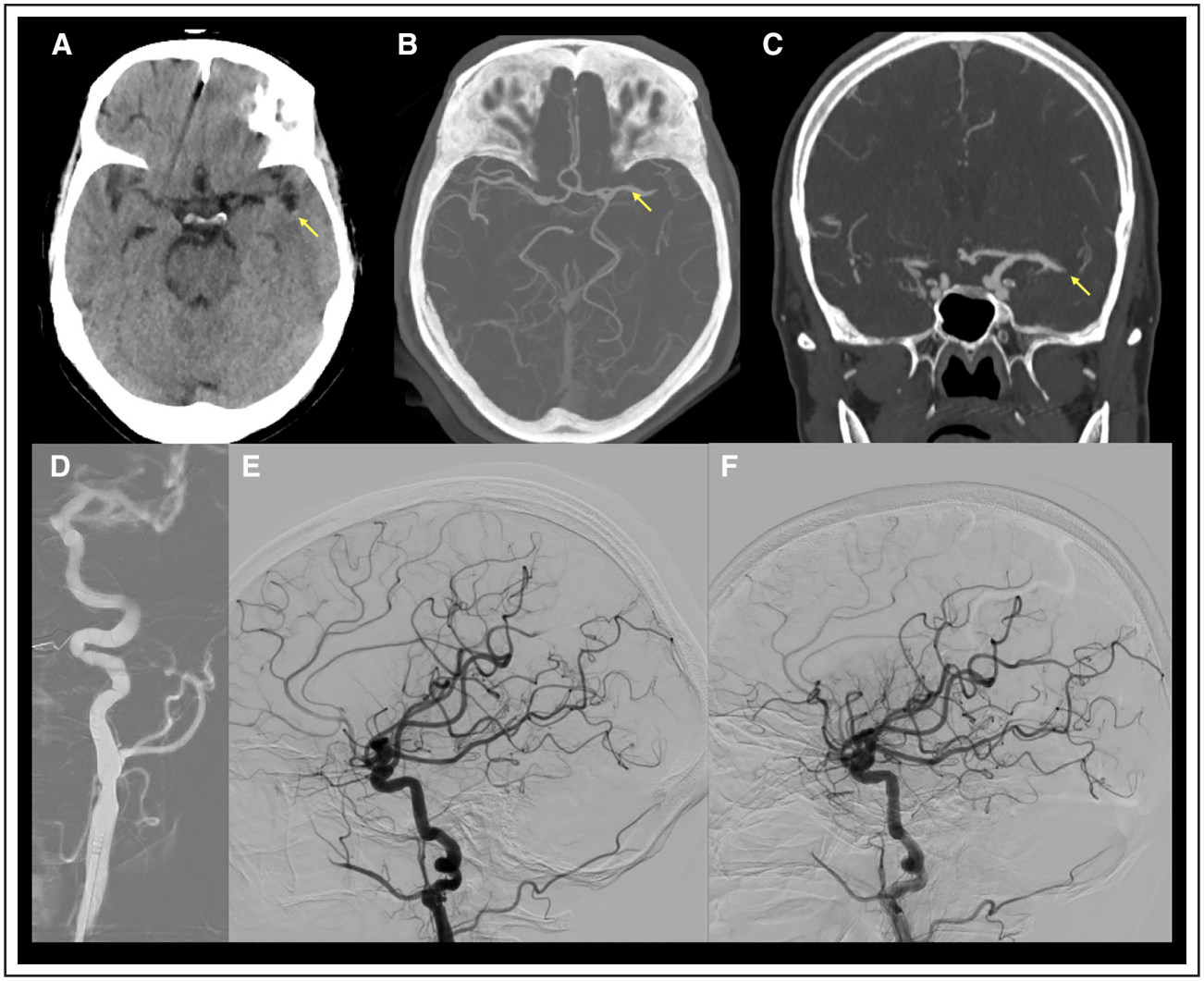

Figure 4. A female patient in her 60s presented with a sudden onset of gaze deviation, right-sided hemiparesis, and global aphasia (National Institutes of Health Stroke Scale [NIHSS] score, 24).
Noncontrast computed tomography (CT) head 3 hours from onset (**A**) showed a subtle left-sided hyperdense vessel sign in the Sylvian fissure (arrow in **A**) but no early ischemic changes. CT head and neck angiogram (**B** and **C**) showed a left-sided M1 occlusion (arrows in **B** and **C**). The patient was treated with intravenous tenecteplase and transferred to the neuroangiography suite for endovascular treatment. A roadmap of the left cervical internal carotid artery (**D**) shows marked tortuosity. The first lateral (**E**) angiographic run shows interval thrombus migration with recanalization of the posterior M2 division and a residual anterior M2 division, which is not well seen on standard projections. **F**, A single aspiration thrombectomy attempt was performed and led to improved reperfusion. There was still a persisting anterior middle cerebral artery perfusion deficit (**F**); however, no endovascular target was visualized anymore, and hence, the procedure was stopped. Over the next 24 hours, the patient's NIHSS score improved to 1.

Downloaded from http://ahajournals.org by on March 16, 2026

age was 75 years in ESCAPE-MeVO and 77 years in DISTAL compared with 68 years in the HERMES meta-analysis of LVO EVT trials.[13] In addition, more patients with baseline disability might have been enrolled in the MeVO trials (19.7% of patients in DISTAL had a premorbid mRS score ≥2) than in past LVO EVT trials, where preexisting disability was a nearly universal exclusion criterion.[70] EVT may have been less well tolerated in this older and more frail patient population, particularly when performed under general anesthesia, which was the case in 40% to 50% of patients.

Notably, strokes due to M2 occlusions were not systematically represented in randomized controlled trials: DISCOUNT excluded patients with proximal M2, while DISTAL and ESCAPE-MeVO restricted enrollment to nondominant M2 occlusions. Given prior evidence supporting the benefit of EVT in dominant and proximal M2 occlusions, clinicians should be cautious in generalizing the negative findings of these trials to this subgroup.[20]

Finally, it is probable that not all eligible patients with MeVO were offered enrollment into the trials. It is possible that many physicians, fueled by the enthusiasm of a long series of previous positive EVT trials, preferentially treated younger, more severely affected, and less disabled patients with off-label EVT outside the trial, and generally, those are more likely to benefit from EVT.

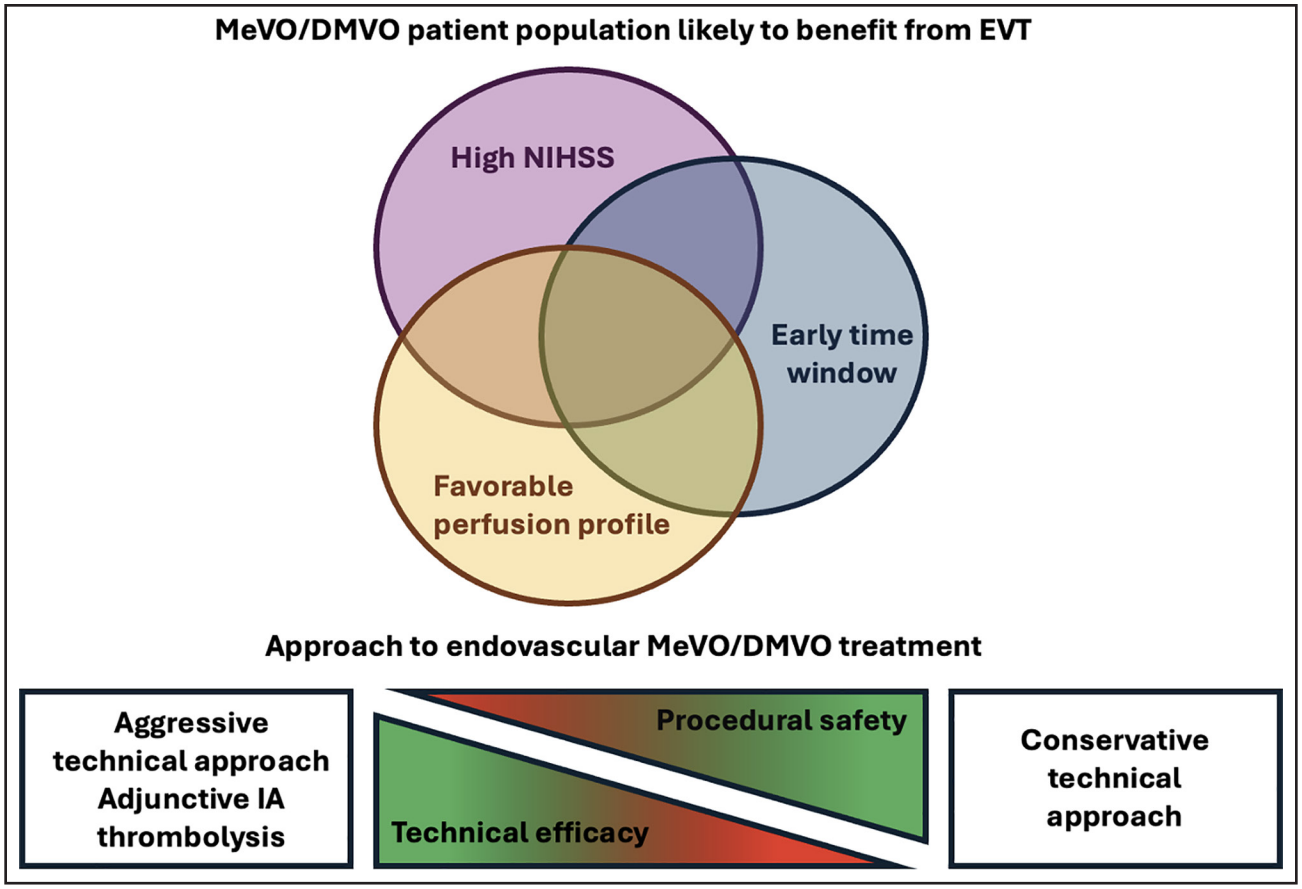

Figure 5. A pathway forward and considerations for future endovascular treatment (EVT) trials in acute stroke due to medium vessel occlusion (MeVO)/distal and medium vessel occlusion (DMVO).
The Venn diagram in the top row schematically illustrates patient subpopulations with MeVO, which, based on randomized trial post hoc analyses, could benefit from EVT. In patients who fit in ≥2 of these subgroups (overlapping areas in the Venn diagram), there may be a higher chance of benefit, but, at the same time, the patient subpopulation decreases in size. The bottom diagram illustrates the tradeoff between conservative EVT approaches (few EVT attempts only and no adjunct treatments), which probably carry a lower complication risk but may also have lower technical efficacy, and more aggressive EVT approaches (several passes and adjunctive intra-arterial [IA] thrombolysis), which may carry a higher complication risk but may also have higher technical efficacy.

Both ESCAPE-MeVO and DISTAL included patients with NIHSS score <5 if they presented with disabling deficits, while, in DISCOUNT, 68% of patients had NIHSS score <10. By contrast, registry data on EVT for MeVO report higher NIHSS scores (10–18) and patients are, on average, 10 years younger than those in randomized controlled trials.[71–74] While this would not have compromised the internal validity of the trial results, it may have affected external validity. In other words, the observed EVT effect truly represents the EVT effect in the enrolled patient population, but the population enrolled may or may not be representative of the general MeVO stroke population. This hypothesis can neither be confirmed nor refuted because screening logs were not maintained.

POSSIBLE WAYS FORWARD

The negative results of the EVT trials in MeVO represent a break in a long-standing series of positive EVT trials in stroke. However, we do not think the results contradict our understanding of the model of AIS; reperfusion remains essential to recovery. Historically, the initial LVO EVT trials were also neutral.[75,76] The lessons learned from these early studies led to a more detailed understanding of the nuances of AIS and laid the groundwork for the landmark successful trials that followed. It is likely that EVT can, in some scenarios, benefit patients with MeVO stroke as well, and the next generation of trials can build on the lessons learned from the first wave of neutral trials.

Improved Patient Selection

While current MeVO trials indicate that EVT is unlikely to benefit most patients with MeVO stroke in the near future, certain subgroups of patients may still benefit. The ORIENTAL-MeVO and full DISCOUNT trial results are expected soon, and results from FRONTIER-AP and RESCUE-M2O, as well as further post hoc analyses

Downloaded from http://ahajournals.org by on March 16, 2026

of the ESCAPE-MeVO and DISTAL trials, may provide more information about subgroups that could benefit from EVT. To delineate the group of patients with MeVO that may benefit from EVT, particularly in those with more distal occlusions, a combination of factors could be used, including early treatment, a favorable perfusion profile, and moderate-to-severe clinical deficits (Figure 5).[5,77,78] In summary, direct or indirect evidence that a large, or at least eloquent, brain region is salvageable through immediate reperfusion is likely critical to emulate, at least partially, the benefits seen in LVO.

Technical Improvements and Adjunct Endovascular Treatments

Technical EVT efficacy in the recent MeVO EVT trials was lower than in LVO stroke, with a final eTICI score of 2b-3 rates ≤75%. Technological advances in devices specifically designed for MeVO-size vessels with improved navigability and potentially safer profiles, along with increased operator experience, are likely to improve reperfusion quality and procedural times.[3] Furthermore, several trials of adjunctive intra-arterial thrombolysis have shown promising results in patients with LVO.[79] This approach targets incomplete reperfusion and the no-reflow phenomenon, which are contributors to poor outcomes despite successful recanalization.[80] A meta-analysis of intra-arterial thrombolysis in anterior circulation LVOs showed a more pronounced treatment effect in trials that included patients with eTICI score of 2b50–3 (odds ratio for mRS score, 0–1, 1.75 [95% CI, 1.35–2.26]) compared with those with eTICI score of 2c–3 (odds ratio, 1.22 [95% CI, 0.96–1.56]).[81] These findings suggest that patients with residual MeVOs and distal occlusions, represented in the Thrombolysis in Cerebral Infarction 2b group, may benefit from adjunctive intra-arterial thrombolysis (Figure S1). Thus, it seems likely that intra-arterial thrombolysis can serve as an adjunct or alternative strategy for patients with MeVO although prospective studies are clearly needed to investigate this.

CONCLUSIONS

MeVOs are a common cause of stroke and cause substantial disability despite the best medical management that includes IV thrombolysis. Recent randomized trials have investigated the benefit of EVT for MeVO stroke, showing no difference in outcomes between EVT and best medical management, and a possibility of harm with EVT. However, preliminary post hoc analyses have identified patient subgroups that may derive benefit from EVT, namely, patients who present early, with substantial clinical deficits and a favorable imaging profile. Results of ongoing and future trials such as DISTAL, FRONTIER-AP, RESCUE-M2O, and ORIENTAL-MeVO will further aid in delineating patients with high chances of EVT benefit. Future EVT trials in MeVO stroke could focus on these patient subgroups and use adjunctive intra-arterial thrombolysis to improve reperfusion success. The clinical eloquence of the vascular territory involved, rather than vessel size alone, should be prioritized in decision-making around reperfusion strategies.

ARTICLE INFORMATION

Affiliations

Faculty of Medical and Health Sciences, Department of Medicine, University of Auckland, New Zealand (W.K.D.). Department of Neurology, John Hunter Hospital, Hunter New England Local Health District, New Lambton, NSW, Australia (W.K.D.). Department of Neurology, Istituto di Ricovero e Cura a Carattere Scientifico (IRCCS) Humanitas Research Hospital, Milan, Italy (U.P.). Department of Biomedical Sciences, Humanitas University, Milan, Italy (U.P.). Department of Clinical Neurosciences (M.A., B.K.M., M.D.H.) and Department of Diagnostic Imaging (B.K.M., M.G., M.D.H., J.M.O.), Foothills Medical Centre, University of Calgary, AB, Canada. Section of Neuroradiology, Department of Radiology, University Hospital Basel, Switzerland (M.-N.P.). Department of Neurology, University Hospital Bern, Switzerland (U.F.). Department of Neuroradiology, Hôpital Pitié-Salpêtrière, Sorbonne Université, Paris, France (F.C.). Department of Neuroradiology, Alfried Krupp Krankenhaus Essen, Germany (R.C.). The First Affiliated Hospital of University of Science and Technology of China, Hefei (W.H.). Department of Neurology, Boston Medical Centre, MA (T.N.N.). Department of Neurosurgery, Hyogo Medical University, Japan (S.Y., K.U.). Department of Neurology, The Royal Melbourne Hospital, Parkville, VIC, Australia (B.Y.).

Sources of Funding

Dr Diprose is supported by the Neurological Foundation of New Zealand.

Disclosures

Dr Psychogios reports travel support from Penumbra, Inc, Stryker Neurovascular, Inc, Medtronic, phenox, Inc, and Siemens Healthineers AG; grants from phenox, Inc, Siemens Healthineers AG, the Swiss National Science Foundation (SNF), Bangerter-Rhyner Stiftung, Stryker Neurovascular, Inc, Penumbra, Inc, Rapid Medical Ltd, and Medtronic; and compensation from Siemens Healthineers AG for consultant services. Dr Fischer reports grants from Boehringer Ingelheim, SNF, AbbVie, and the Swiss Heart Foundation to others; compensation from Takeda California, Inc, Bayer Healthcare, Siemens Healthcare, and AstraZeneca for consultant services; grants from Medtronic Vascular, Inc, Penumbra, Inc, Rapid Medical Ltd, phenox, Inc, and Biogen Idec; and compensation from the CSL Behring Foundation for Research and Advancement of Patient Health and Stryker Corporation for other services. Dr Clarençon reports compensation from Balt USA, LLC, phenox, Inc, Stryker, Artedrone, and Medtronic for consultant services and compensation from Penumbra, Inc, for other services. Dr Chapot reports stock holdings in Bendit; compensation from Balt USA, LLC, and Rapid Medical Ltd for other services; compensation from MicroVention, Inc, for data and safety monitoring services; and compensation from Siemens Healthcare for other services. Dr Nguyen reports compensation from Brainomix, Medtronic, and Route 92 Medical, Inc, for consultant services and compensation from Genentech, the American Stroke Association, and Kaneka for other services. Dr Yoshimura reports compensation from Idorsia, Johnson & Johnson Health Care Systems, Inc, Stryker, Kaneka Medics, Termo, Daiichi Sankyo Company, and Medtronic for other services and grants from Eisai Co, Ltd. Dr Uchida reports compensation from Medtronic, Daiichi Sankyo Company Ltd, and Stryker for other services. Dr Goyal reports compensation from Medtronic, MicroVention, Inc, and Mentice for consultant services; grants from Medtronic and Johnson & Johnson Health Care Systems, Inc, to others; and stock holdings in Collavidence. Dr Hill reports grants from the Canadian Institutes of Health Research, NoNO, Inc, Boehringer Ingelheim, and Medtronic; stock options in Basking Bioscience LLC; and employment by the University of Calgary. Dr Ospel reports grants from Medtronic and employment by the Foothills Medical Center, University of Calgary. The other authors report no conflicts.

Supplemental Material

Appendix S1
Tables S1–S2
Figure S1

Downloaded from http://ahajournals.org by on March 16, 2026

REFERENCES

1. GBD 2021 Stroke Risk Factor Collaborators. Global, regional, and national burden of stroke and its risk factors, 1990-2021: a systematic analysis for the Global Burden of Disease Study 2021. *Lancet Neurol*. 2024;23:973–1003. doi: 10.1016/S1474-4422(24)00369-7
2. Saver JL. Time is brain—quantified. *Stroke*. 2006;37:263–266. doi: 10.1161/01.STR.0000196957.55928.ab
3. Saver JL, Chapot R, Agid R, Hassan A, Jadhav AP, Liebeskind DS, Lobotesis K, Meila D, Meyer L, Raphaeli G, et al; Distal Thrombectomy Summit Group. Thrombectomy for distal, medium vessel occlusions. *Stroke*. 2020;51:2872–2884. doi: 10.1161/STROKEAHA.120.028956
4. Ospel JM, Menon BK, Demchuk AM, Almekhlafi MA, Kashani N, Mayank A, Fainardi E, Rubiera M, Khaw A, Shankar JJ, et al. Clinical course of acute ischemic stroke due to medium vessel occlusion with and without intravenous alteplase treatment. *Stroke*. 2020;51:3232–3240. doi: 10.1161/STROKEAHA.120.030227
5. Goyal M, Ospel JM, Ganesh A, Dowlatshahi D, Volders D, Möhlenbruch MA, Jumaa MA, Nimjee SM, Booth TC, Buck BH, et al; ESCAPE-MeVO Investigators. Endovascular treatment of stroke due to medium-vessel occlusion. *N Engl J Med*. 2025;392:1385–1395. doi: 10.1056/NEJMoa2411668
6. Psychogios M, Brehm A, Ribo M, Rizzo F, Strbian D, Räty S, Arenillas JF, Martínez-Galdámez M, Hajdu SD, Michel P, et al; DISTAL Investigators. Endovascular treatment for stroke due to occlusion of medium or distal vessels. *N Engl J Med*. 2025;392:1374–1384. doi: 10.1056/NEJMoa2408954
7. Pensato U, Demchuk AM, Menon BK, Nguyen TN, Broocks G, Campbell BCV, Gutierrez Vasquez DA, Mitchell PJ, Hill MD, Goyal M, et al. Cerebral infarct growth: pathophysiology, pragmatic assessment, and clinical implications. *Stroke*. 2025;56:219–229. doi: 10.1161/STROKEAHA.124.049013
8. Emberson J, Lees KR, Lyden P, Blackwell L, Albers G, Bluhmki E, Brott T, Cohen G, Davis S, Donnan G, et al; Stroke Thrombolysis Trialists' Collaborative Group. Effect of treatment delay, age, and stroke severity on the effects of intravenous thrombolysis with alteplase for acute ischaemic stroke: a meta-analysis of individual patient data from randomised trials. *Lancet*. 2014;384:1929–1935. doi: 10.1016/S0140-6736(14)60584-5
9. Powers WJ, Rabinstein AA, Ackerson T, Adeoye OM, Bambakidis NC, Becker K, Biller J, Brown M, Demaerschalk BM, Hoh B, et al. Guidelines for the early management of patients with acute ischemic stroke: 2019 update to the 2018 guidelines for the early management of acute ischemic stroke: a guideline for healthcare professionals from the American Heart Association/American Stroke Association. *Stroke*. 2019;50:e344–e418. doi: 10.1161/STR.0000000000000211
10. Majoie CB, Cavalcante F, Gralla J, Yang P, Kaesmacher J, Treurniet KM, Kappelhof M, Yan B, Suzuki K, Zhang Y, et al; IRIS collaborators. Value of intravenous thrombolysis in endovascular treatment for large-vessel anterior circulation stroke: individual participant data meta-analysis of six randomised trials. *Lancet*. 2023;402:965–974. doi: 10.1016/S0140-6736(23)01142-X
11. Zhou Y, He Y, Campbell BCV, Liebeskind DS, Yuan C, Chen H, Zhang Y, Yi T, Luo Z, Zhang Z, et al; HOPE investigators. Alteplase for acute ischemic stroke at 4.5 to 24 hours: the HOPE randomized clinical trial. *JAMA*. 2025;334:788–797. doi: 10.1001/jama.2025.12063
12. Guo Y, Xu Y-G, Liu C, Zhang H-Z, Luo W. Bridging thrombolysis before endovascular therapy is associated with better outcomes in patients with large infarction core. *J Neurointerv Surg*. 2025;17:e222–e230. doi: 10.1136/jnis-2024-021958
13. Goyal M, Menon BK, van Zwam WH, Dippel DWJ, Mitchell PJ, Demchuk AM, Dávalos A, Majoie CBLM, van der Lugt A, de Miquel MA, et al; HERMES collaborators. Endovascular thrombectomy after large-vessel ischaemic stroke: a meta-analysis of individual patient data from five randomised trials. *Lancet*. 2016;387:1723–1731. doi: 10.1016/S0140-6736(16)00163-X
14. Nogueira RG, Jovin TG, Liu X, Hu W, Langezaal LCM, Li C, Dai Q, Tao C, Mont'Alverne FJA, Ji X, et al; ATTENTION, BASICS, BAOCHE, and BEST Investigators. Endovascular therapy for acute vertebrobasilar occlusion (VERITAS): a systematic review and individual patient data meta-analysis. *Lancet*. 2025;405:61–69. doi: 10.1016/S0140-6736(24)01820-8
15. Jovin TG, Nogueira RG, Lansberg MG, Demchuk AM, Martins SO, Mocco J, Ribo M, Jadhav AP, Ortega-Gutierrez S, Hill MD, et al. Thrombectomy for anterior circulation stroke beyond 6 h from time last known well (AURORA): a systematic review and individual patient data meta-analysis. *Lancet*. 2022;399:249–258. doi: 10.1016/S0140-6736(21)01341-6
16. Nguyen TN, Nogueira RG, Qureshi MM, Nagel S, Raymond J, Abdalkader M, Demeestere J, Marto JP, Sheth SA, Puetz V, et al. Noncontrast CT selected thrombectomy vs medical management for late-window anterior large vessel occlusion. *Neurology*. 2024;102:e209324. doi: 10.1212/WNL.0000000000209324
17. Khan F, Yogendrakumar V, Menon BK. Endovascular thrombectomy for ischemic stroke with large infarct. *Stroke*. 2025;56:1655–1658. doi: 10.1161/STROKEAHA.125.050897
18. Clarençon F, Durand-Zaleski I, Premat K, Baptiste A, Chabert E, Ferrier A, Labeyrie M-A, Reiner P, Spelle L, Denier C, et al. Evaluation of mechanical thrombectomy in acute ischemic stroke related to a distal arterial occlusion: a randomized controlled trial. *Int J Stroke*. 2024;19:367–372. doi: 10.1177/17474930231205213
19. Palaiodimou L, Safouris A, Papageorgiou NM, Melanis K, Magoufis G, Theodorou A, Spiliopoulos S, Mantatzis MM, Themistocleous M, Toutouzas K, et al. Endovascular treatment in acute ischemic stroke due to occlusion of medium or distal vessels: a systematic review and meta-analysis. *Neurology*. 2025;105:e214015. doi: 10.1212/WNL.0000000000214015
20. Mehta A, Goldman D, Raz E, Desai S, Mistry E, Nguyen T, Sheth S, Jadhav A, Broderick J, Khatri P, et al. Should we stop endovascular treatment of M2 occlusions?: a critical look at recent evidence. *Stroke*. 2025;56:2819–2829. doi: 10.1161/STROKEAHA.125.051578
21. Cilliers K, Page BJ. Anatomy of the middle cerebral artery: cortical branches, branching pattern and anomalies. *Turk Neurosurg*. 2017;27:671–681. doi: 10.5137/1019-5149.JTN.18127-16.1
22. Jing X, Nogueira RG, Nguyen TN, Tao C, Zhu Y, Li R, Sun J, Wang L, Zhang C, Liu T, et al. Endovascular treatment in acute intracranial distal medium vessel occlusion stroke: study protocol and rationale. *Int J Stroke*. 2025;20:763–768. doi: 10.1177/17474930251332753
23. Mirza M, Brouwer P. E-058 Distal vessel occlusion definitions for acute ischemic stroke and their discordance. In: SNIS 21st annual meeting electronic poster abstracts. BMA House, Tavistock Square, London, WC1H 9JR: BMJ Publishing Group Ltd; 2024:A116–A116.
24. Rodriguez-Calienes A, Vivanco-Suarez J, Dibas M, Casanova D, Galecio-Castillo M, Farooqui M, Ortega-Gutierrez S. Current challenges in the endovascular treatment of medium vessel occlusions. *Front. Stroke*. 2023;2:1242961. doi: 10.3389/fstro.2023.1242961
25. Shapiro M, Raz E, Nossek E, Chancellor B, Ishida K, Nelson PK. Neuroanatomy of the middle cerebral artery: implications for thrombectomy. *J Neurointerv Surg*. 2020;12:768–773. doi: 10.1136/neurintsurg-2019-015782
26. Gibo H, Carver CC, Rhoton AL Jr, Lenkey C, Mitchell RJ. Microsurgical anatomy of the middle cerebral artery. *J Neurosurg*. 1981;54:151–169. doi: 10.3171/jns.1981.54.2.0151
27. Pillai P, Mitchell PJ, Phan TG, Ma H, Yan B. Angiographic systems for classifying distal arterial occlusions. *Cerebrovasc Dis*. 2023;52:353–362. doi: 10.1159/000526873
28. Gruber P, Valbuena P, Sassenburg R, Anon J, Andereggen L, Berberat J, Remonda L. Anatomical distribution and clinical significance of middle cerebral artery M2 segment vessel occlusions and its cortical branches in acute ischaemic stroke patients. *BMJ Neurol Open*. 2023;5:e000450. doi: 10.1136/bmjno-2023-000450
29. Mohammaden MH, Souza Viana L, Abdelhamid H, Olive-Gadea M, Rodrigo-Gisbert M, Requena M, Martins PN, Matsoukas S, Schuldt BR, Fifi JT, et al. Endovascular versus medical management in distal medium vessel occlusion stroke: the DUSK study. *Stroke*. 2024;55:1489–1497. doi: 10.1161/STROKEAHA.123.045228
30. Hoffmann M. Isolated right temporal lobe stroke patients present with Geschwind-Gastaut syndrome, frontal network syndrome and delusional misidentification syndromes. *Behav Neurol*. 2008;20:83–89. doi: 10.3233/BEN-2008-0218
31. Abdalkader M, Sahoo A, Dmytriw AA, Brinjikji W, Dabus G, Raz E, Renieri L, Laiso A, Maud A, Martínez-Galdámez M, et al. Mechanical thrombectomy of the fetal posterior cerebral artery. *Stroke Vasc Interv Neurol*. 2023;1:e000115. doi: 10.1161/SVIN.121.000115
32. Benke T, Dazinger F, Pechlaner R, Willeit K, Clausen J, Knoflach M. Lesion topography of posterior cerebral artery infarcts. *J Neurol Sci*. 2021;428:117585. doi: 10.1016/j.jns.2021.117585
33. Schmahmann JD. Vascular syndromes of the thalamus. *Stroke*. 2003;34:2264–2278. doi: 10.1161/01.STR.0000087786.38997.9E
34. Park H, Jeong YS, Lee SH, Jang SH, Kwon DH, Hong J-H, Sohn S-I, Yoo J. Clinical prognosis of isolated anterior cerebral artery territory infarction: a retrospective study. *BMC Neurol*. 2021;21:171. doi: 10.1186/s12883-021-02194-9
35. García Carretero R, Beamonte-Vela B-N, Silvano-Cocinero J-D, Alvarez-Mendez A. Behavioural changes as the first manifestation of a silent frontal lobe stroke. *BMJ Case Rep*. 2019;12:bcr–2018. doi: 10.1136/bcr-2018-227617
36. Menon BK, Hill MD, Davalos A, Roos YBWEM, Campbell BCV, Dippel DWJ, Guillemin F, Saver JL, van der Lugt A, Demchuk AM, et al. Efficacy of endovascular thrombectomy in patients with M2 segment middle cerebral artery

Downloaded from http://ahajournals.org by on March 16, 2026

occlusions: meta-analysis of data from the HERMES collaboration. *J Neurointerv Surg*. 2019;11:1065–1069. doi: 10.1136/neurintsurg-2018-014678
37. Smith WS, Lev MH, English JD, Camargo EC, Chou M, Johnston SC, Gonzalez G, Schaefer PW, Dillon WP, Koroshetz WJ, et al. Significance of large vessel intracranial occlusion causing acute ischemic stroke and TIA. *Stroke*. 2009;40:3834–3840. doi: 10.1161/STROKEAHA.109.561787
38. Meyer L, Stracke P, Broocks G, Elsharkawy M, Sporns P, Piechowiak EI, Kaesmacher J, Maegerlein C, Hernandez Petzsche MR, Zimmermann H, et al; TOPMOST Study Group. Thrombectomy versus medical management for isolated anterior cerebral artery stroke: an international multicenter registry study. *Radiology*. 2023;307:e220229. doi: 10.1148/radiol.220229
39. Nguyen TN, Qureshi MM, Strambo D, Strbian D, Räty S, Herweh C, Abdalkader M, Olive-Gadea M, Ribo M, Psychogios M, et al. Endovascular versus medical management of posterior cerebral artery occlusion stroke: the PLATO study. *Stroke*. 2023;54:1708–1717. doi: 10.1161/STROKEAHA.123.042674
40. Meyer L, Stracke CP, Jungi N, Wallocha M, Broocks G, Sporns PB, Maegerlein C, Dorn F, Zimmermann H, Naziri W, et al. Thrombectomy for primary distal posterior cerebral artery occlusion stroke: the TOPMOST study. *JAMA Neurol*. 2021;78:434–444. doi: 10.1001/jamaneurol.2021.0001
41. Menon BK, Buck BH, Singh N, Deschaintre Y, Almekhlafi MA, Coutts SB, Thirunavukkarasu S, Khosravani H, Appireddy R, Moreau F, et al; AcT Trial Investigators. Intravenous tenecteplase compared with alteplase for acute ischaemic stroke in Canada (AcT): a pragmatic, multicentre, open-label, registry-linked, randomised, controlled, non-inferiority trial. *Lancet*. 2022;400:161–169. doi: 10.1016/S0140-6736(22)01054-6
42. Ma H, Campbell BCV, Parsons MW, Churilov L, Levi CR, Hsu C, Kleinig TJ, Wijeratne T, Curtze S, Dewey HM, et al; EXTEND Investigators. Thrombolysis guided by perfusion imaging up to 9 hours after onset of stroke. *N Engl J Med*. 2019;380:1795–1803. doi: 10.1056/NEJMoa1813046
43. Thomalla G, Simonsen CZ, Boutitie F, Andersen G, Berthezene Y, Cheng B, Cheripelli B, Cho T-H, Fazekas F, Fiehler J, et al; WAKE-UP Investigators. MRI-guided thrombolysis for stroke with unknown time of onset. *N Engl J Med*. 2018;379:611–622. doi: 10.1056/NEJMoa1804355
44. Galinovic I, Fiebach JB, Boutitie F, Cheng B, Cho T-H, Ebinger M, Endres M, Enzinger C, Fiehler J, Ford I, et al; for WAKE-UP Investigators. Effect of IV thrombolysis with alteplase in patients with vessel occlusion in the WAKE-UP trial. *Neurology*. 2025;104:e209871. doi: 10.1212/WNL.0000000000209871
45. Coutts SB, Ankolekar S, Appireddy R, Arenillas JF, Assis Z, Bailey P, Barber PA, Bazan R, Buck BH, Butcher KS, et al; TEMPO-2 investigators. Tenecteplase versus standard of care for minor ischaemic stroke with proven occlusion (TEMPO-2): a randomised, open label, phase 3 superiority trial. *Lancet*. 2024;403:2597–2605. doi: 10.1016/S0140-6736(24)00921-8
46. Bala F, Singh N, Ignacio K, Alhabli I, Ademola A, Alrohimi A, Khosravani H, Tkach A, Catanese L, Dowlatshahi D, et al. Tenecteplase versus alteplase in medium vessel occlusion ischemic stroke: a secondary analysis of the alteplase compared to tenecteplase randomized trial. *J Stroke*. 2024;26:280–289. doi: 10.5853/jos.2023.03713
47. Muir KW. Should we switch to tenecteplase for all ischemic strokes? Evidence and logistics. *Int J Stroke*. 2025;20:261–267. doi: 10.1177/17474930241307098
48. Palaiodimou L, Katsanos AH, Turc G, Asimakopoulos A-G, Mavridis D, Schellinger PD, Theodorou A, Lemmens R, Sacco S, Safouris A, et al. Tenecteplase vs alteplase in acute ischemic stroke within 4.5 hours: a systematic review and meta-analysis of randomized trials. *Neurology*. 2024;103:e209903. doi: 10.1212/WNL.0000000000209903
49. Berge E, Whiteley W, Audebert H, De Marchis GM, Fonseca AC, Padiglioni C, de la Ossa NP, Strbian D, Tsivgoulis G, Turc G. European Stroke Organisation (ESO) guidelines on intravenous thrombolysis for acute ischaemic stroke. *Eur Stroke J*. 2021;6:I–LXII. doi: 10.1177/2396987321989865
50. Heran M, Lindsay P, Gubitz G, Yu A, Ganesh A, Lund R, Arsenault S, Bickford D, Derbyshire D, Doucette S, et al. Canadian stroke best practice recommendations: acute stroke management, 7th edition practice guidelines update, 2022. *Can J Neurol Sci*. 2024;51:1–31. doi: 10.1017/cjn.2022.344
51. Räty S, Nguyen TN, Nagel S, Strambo D, Michel P, Herweh C, Qureshi MM, Abdalkader M, Virtanen P, Olive-Gadea M, et al. Endovascular thrombectomy versus intravenous thrombolysis of posterior cerebral artery occlusion stroke. *J Stroke*. 2024;26:290–299. doi: 10.5853/jos.2024.00458
52. Salim HA, Yedavalli V, Musmar B, Adeeb N, Essibayi MA, Naamani KE, Henninger N, Sundararajan SH, Kühn AL, Khalife J, et al; MAD MT Investigators. Mechanical thrombectomy versus intravenous thrombolysis in distal medium vessel acute ischemic stroke: a multinational multicenter propensity score-matched study. *J Stroke*. 2024;26:434–445. doi: 10.5853/jos.2024.01389
53. Ospel JM, Goyal M. A review of endovascular treatment for medium vessel occlusion stroke. *J Neurointerv Surg*. 2021;13:623–630. doi: 10.1136/neurintsurg-2021-017321
54. Ospel JM, Dowlatshahi D, Demchuk A, Volders D, Möhlenbruch M, Nimjee S, Kennedy J, Buck B, Shankar JJ, Booth TC, et al; ESCAPE-MeVO investigators. Endovascular treatment to improve outcomes for medium vessel occlusions: the ESCAPE-MeVO trial. *Int J Stroke*. 2024;19:1064–1070. doi: 10.1177/17474930241262642
55. Marios-Nikos P, Alex B, Jens F, Isabel F, Jan G, Mira K, Ronen L, Paolo M, Marc R, Jeffrey LS, et al. Endovascular therapy plus best medical treatment (BMT) versus BMT alone for medium distal vessel occlusion stroke (DISTAL): an international, multicentre, randomized-controlled, two-arm, assessor-blinded trial. *Eur Stroke J*. 2024;9:1083–1092. doi: 10.1177/23969873241250212
56. Ospel JM, Diprose WK, Uchida K, Möhlenbruch MA, Volders D, Jumaa MA, Nimjee S, Dowlatshahi D, Bosshart SL, Stebner A, et al. Association of imaging features with outcomes and effect of reperfusion therapies in MeVO stroke. *Radiology*. 2025; In press.
57. Hill MD, Goyal M, Demchuk AM, Menon BK, Field TS, Guest WC, Berrouschot J, Bormann A, Pham M, Haeusler KG, et al; ESCAPE-NEXT Investigators. Efficacy and safety of nerinetide in acute ischaemic stroke in patients undergoing endovascular thrombectomy without previous thrombolysis (ESCAPE-NEXT): a multicentre, double-blind, randomised controlled trial. *Lancet*. 2025;405:560–570. doi: 10.1016/S0140-6736(25)00194-1
58. Diprose W, Fahed R, Volders D, Möhlenbruch MA, Jumaa M, Nimjee SM, Ganesh A, Booth TC, Buck BH, Kennedy J, et al. Reperfusion grade and clinical outcome following medium vessel occlusion thrombectomy in the Endovascular Treatment to Improve Outcomes for Medium Vessel Occlusions (ESCAPE-MeVO) Trial [published online February 6, 2026]. *J Neurointerv Surg*. 2026. doi: 10.1136/jnis-2025-024733
59. Saver JL, Goyal M, van der Lugt A, Menon BK, Majoie CBLM, Dippel DW, Campbell BC, Nogueira RG, Demchuk AM, Tomasello A, et al; HERMES Collaborators. Time to treatment with endovascular thrombectomy and outcomes from ischemic stroke: a meta-analysis. *JAMA*. 2016;316:1279–1288. doi: 10.1001/jama.2016.13647
60. Goyal M, Ganesh A, Bosshart SL, Stebner A, Singh N, Menon BK, Coutts SB, Ospel JM, Almekhlafi MA, Kromm J, et al. COSMOS: interrater and intrarater reliability study of a novel outcome measure. *Stroke*. 2025;56:1958–1964. doi: 10.1161/STROKEAHA.125.049454
61. Pensato U, Stebner A, Bosshart S, Shah R, Rohr A, Hanel R, Kelly ME, Bharatha A, Hill MD, Goyal M, et al. Combining computed tomography perfusion and baseline National Institutes of Health Stroke Scale to assess the clinical penumbra in ischemic stroke. *J Stroke*. 2025;27:270–274. doi: 10.5853/jos.2024.03720
62. Menezes NM, Ay H, Wang Zhu M, Lopez CJ, Singhal AB, Karonen JO, Aronen HJ, Liu Y, Nuutinen J, Koroshetz WJ, et al. The real estate factor. *Stroke*. 2007;38:194–197. doi: 10.1161/01.STR.0000251792.76080.45
63. Bala F, Singh N, Buck B, Ademola A, Coutts SB, Deschaintre Y, Khosravani H, Appireddy R, Moreau F, Phillips S, et al. Safety and efficacy of tenecteplase compared with alteplase in patients with large vessel occlusion stroke: a prespecified secondary analysis of the AcT randomized clinical trial. *JAMA Neurol*. 2023;80:824–832. doi: 10.1001/jamaneurol.2023.2094
64. Campbell BCV, Mitchell PJ, Churilov L, Yassi N, Kleinig TJ, Dowling RJ, Yan B, Bush SJ, Dewey HM, Thijs V, et al; EXTEND-IA TNK Investigators. Tenecteplase versus alteplase before thrombectomy for ischemic stroke. *N Engl J Med*. 2018;378:1573–1582. doi: 10.1056/NEJMoa1716405
65. Lee H, Qureshi AM, Mueller-Kronast NH, Zaidat OO, Froehler MT, Liebeskind DS, Pereira VM. Subarachnoid hemorrhage in mechanical thrombectomy for acute ischemic stroke: analysis of the STRATIS registry, systematic review, and meta-analysis. *Front Neurol*. 2021;12:663058. doi: 10.3389/fneur.2021.663058
66. Liu J, Zhou Y, Zhang L, Li Z, Chen W, Zhu Y, Yao X, Zhang L, Liu S, Peng Y, et al; PROTECT-MT Investigators. Balloon guide catheters for endovascular thrombectomy in patients with acute ischaemic stroke due to large-vessel occlusion in China (PROTECT-MT): a multicentre, open-label, blinded-endpoint, randomised controlled trial. *Lancet*. 2024;404:2165–2174. doi: 10.1016/S0140-6736(24)02315-8
67. Nguyen TN, Malisch T, Castonguay AC, Gupta R, Sun C-HJ, Martin CO, Holloway WE, Mueller-Kronast N, English JD, Linfante I, et al. Balloon guide catheter improves revascularization and clinical outcomes with the Solitaire device: analysis of the North American Solitaire acute stroke registry. *Stroke*. 2014;45:141–145. doi: 10.1161/STROKEAHA.113.002407
68. Nguyen TN, Castonguay AC, Nogueira RG, Haussen DC, English JD, Satti SR, Chen J, Farid H, Borders C, Veznedaroglu E, et al. Effect of balloon guide catheter on clinical outcomes and reperfusion

Downloaded from http://ahajournals.org by on March 16, 2026

in Trevo thrombectomy. *J Neurointerv Surg*. 2019;11:861–865. doi: 10.1136/neurintsurg-2018-014452
69. Mohammaden MH, Doheim MF, Dolia J, Abdelhamid H, Matsoukas S, Schuldt BR, Fifi JT, Kuybu O, Al-Bayati AR, Olive Gadea M, et al. Balloon guide catheter impact on angiographic and clinical outcomes in distal medium vessel occlusion stroke thrombectomy. *J Neurointerv Surg*. 2025;jnis-2025-023138. doi: 10.1136/jnis-2025-023138
70. Wechsler PM, Leslie-Mazwi T, Mistry EA. Endovascular thrombectomy in patients with preexisting disability: a review. *Stroke Vasc Interv Neurol*. 2024;4:e001326. doi: 10.1161/SVIN.124.001326
71. Grossberg JA, Rebello LC, Haussen DC, Bouslama M, Bowen M, Barreira CM, Belagaje SR, Frankel MR, Nogueira RG. Beyond large vessel occlusion strokes: distal occlusion thrombectomy. *Stroke*. 2018;49:1662–1668. doi: 10.1161/STROKEAHA.118.020567
72. Alawieh AM, Chalhoub RM, Al Kasab S, Jabbour P, Psychogios M-N, Starke RM, Arthur AS, Fargen KM, De Leacy R, Kan P, et al; STAR Collaborators. Multicenter investigation of technical and clinical outcomes after thrombectomy for distal vessel occlusion by frontline technique. *J Neurointerv Surg*. 2023;15:e93–e101. doi: 10.1136/jnis-2022-019023
73. Altenbernd J, Kuhnt O, Hennigs S, Hilker R, Loehr C. Frontline ADAPT therapy to treat patients with symptomatic M2 and M3 occlusions in acute ischemic stroke: initial experience with the Penumbra ACE and 3MAX reperfusion system. *J Neurointerv Surg*. 2018;10:434–439. doi: 10.1136/neurintsurg-2017-013233
74. Alessiani M, Bonura A, Iaccarino G, Rossi SS, Mangiardi M, Bravi MC, Pezzella FR, de Rubeis G, Pampana E, Anticoli S. Safety and efficacy of mechanical thrombectomy in distal medium vessel occlusions: experience and real-world data from an Italian stroke hub centre. *J Stroke Cerebrovasc Dis*. 2025;34:108321. doi: 10.1016/j.jstrokecerebrovasdis.2025.108321
75. Smith WS, Furlan AJ. Brief history of endovascular acute ischemic stroke treatment. *Stroke*. 2016;47:e23–e26. doi: 10.1161/STROKEAHA.115.010863
76. Nguyen TN, Abdalkader M, Fischer U, Qiu Z, Nagel S, Chen H-S, Miao Z, Khatri P. Endovascular management of acute stroke. *Lancet*. 2024;404:1265–1278. doi: 10.1016/S0140-6736(24)01410-7
77. Strambo D, Michel P, Nguyen TN, Abdalkader M, Qureshi MM, Strbian D, Herweh C, Möhlenbruch MA, Räty S, Olivé-Gadea M, et al. Endovascular versus medical therapy in posterior cerebral artery stroke: role of baseline NIHSS score and occlusion site. *Stroke*. 2024;55:1787–1797. doi: 10.1161/STROKEAHA.124.047383
78. Broocks G, Mannoun M, Bechstein M, Kniep H, Winkelmeier L, Schön G, Heitkamp C, Papanagiotou P, Kemmling A, Alfke K, et al. Penumbral imaging to guide endovascular treatment for M2 middle cerebral artery stroke. *Stroke*. 2025;56:138–147. doi: 10.1161/STROKEAHA.124.048637
79. Almekhlafi MA, Park H, Singh N, Lun R, Pensato U, Ignacio K, Ospel J, Ganesh A, Alshamrani M, Demchuk AM, et al. Adjunctive intraarterial thrombolysis after thrombectomy in large vessel occlusion stroke: a meta-analysis of RCTs. *Can J Neurol Sci*. 2025;1–9. doi: 10.1017/cjn.2025.10354
80. Mujanovic A, Ng F, Meinel TR, Dobrocky T, Piechowiak EI, Kurmann CC, Seiffge DJ, Wegener S, Wiest R, Meyer L, et al. No-reflow phenomenon in stroke patients: a systematic literature review and meta-analysis of clinical data. *Int J Stroke*. 2024;19:58–67. doi: 10.1177/17474930231180434
81. Alkhiri A, Alturki F, Alamri AF, Salamatullah HK, Almaghrabi AA, Alshaikh H, Aljohani A, Hakami A, M Alrohimi A, Al-Ajlan FS, et al. Adjunctive intra-arterial thrombolysis after successful endovascular thrombectomy for large vessel occlusion: meta-analysis of outcomes, dosage, and patient selection. *J Neurointerv Surg*. 2025;jnis-2025-023404. doi: 10.1136/jnis-2025-023404

Downloaded from http://ahajournals.org by on March 16, 2026